

Photobiomodulation of Pain in Carpal Tunnel Syndrome: Review of Seven Laser Therapy Studies

MARGARET A. NAESER, Ph.D., Lic.Ac.

ABSTRACT

In this review, seven studies using photoradiation to treat carpal tunnel syndrome (CTS) are discussed: two controlled studies that observed real laser to have a better effect than sham laser, to treat CTS; three open-protocol studies that observed real laser to have a beneficial effect to treat CTS; and two studies that did not observe real laser to have a better effect than a control condition, to treat CTS. In the five studies that observed beneficial effect from real laser, higher laser dosages (9 Joules, 12–30 Joules, 32 J/cm², 225 J/cm²) were used at the primary treatment sites (median nerve at the wrist, or cervical neck area), than dosages in the two studies where real laser was not observed to have a better effect than a control condition (1.8 Joules or 6 J/cm²). The average success rate across the first five studies was 84% (SD, 8.9; total hands = 171). The average pain duration prior to successful photoradiation was 2 years. Photoradiation is a promising new, conservative treatment for mild/moderate CTS cases (motor latency < 7 msec; needle EMG, normal). It is cost-effective compared to current treatments.

INTRODUCTION

PAIN IN CARPAL TUNNEL SYNDROME (CTS) is associated with entrapment neuropathy of the median nerve at the wrist; inflammation is present as the nerve passes from the forearm to the palm, between the transverse carpal ligament and nine flexor tendons.¹ Signs and symptoms include paresthesias, numbness and tingling in the thumb, index, middle and radial side of ring finger, Tinel sign, Phalen sign, hypoesthesia, nocturnal awakening, and sometimes hand weakness.^{2–4} Nerve conduction studies (NCSs) are the primary definitive test, although test results considered compatible with CTS vary across studies.^{1,5,6}

CTS occurs more commonly in workers with tasks involving repetitive hand movements (e.g., computer keyboard typing, assembly line work). It may result from concentration of workload on a few smaller muscle groups.³ Between 1981 and 1991, the U.S. Department of Labor, Bureau of Labor Statistics reported an almost 10-fold increase (from 23,000 to 223,600) in disorders "associated with repeated trauma."^{7,8} In 1995, half of all workers with CTS missed ≥ 30 days of work.⁹

Current standard treatments include, initially, conservative treatments such as adjusting the work environment, using wrist

splints, and nonsteroidal anti-inflammatories (NSAIDs).¹⁰ Direct injection of steroids into the carpal tunnel may provide relief for only 2–4 months,¹¹ and at 18 months, only 22% of patients may be free of symptoms.¹²

Surgical release of the transverse carpal ligament is performed in 40–45% of CTS cases, with estimates of more than 460,000 procedures performed each year, and a direct medical cost of over \$1.9 billion.⁶ Following surgery, approximately one-third of patients continue to experience pain and functional loss¹³; only 40% regain normal function, and 5% worsen.^{14,15} Office workers return to work in a few weeks; those working in heavier labor require 4–6 months of rehabilitation.

In 1993, the cost to treat one CTS case without surgery in California was \$5,246, but with surgery \$20,925.¹⁶ The average cost to treat one CTS case nationwide was about \$12,000.¹⁷ There is a need for new, conservative treatment for CTS that can be applied in the earlier stages, to permit continued employment, prevent disability, and reduce surgery.

Seven studies (Table 1) that used photoradiation (a type of photobiomodulation), as a new, conservative treatment are reviewed: (1) two controlled studies that observed real laser to have a better effect than sham laser, to treat CTS; (2) three open-protocol studies that observed real laser to have a beneficial effect

TABLE 1. SUMMARY OF METHODS AND RESULTS FOR SEVEN STUDIES USING PHOTOBIO-MODULATION TO TREAT PAIN IN CARPAL TUNNEL SYNDROME

Authors and study citation	Subject demographics and study design	Methods			Results	
		Real laser condition	Sham laser condition	Real laser condition	Sham laser condition	
1a. Two controlled studies that observed real laser to have a better effect than sham laser, to treat CTS						
Anderson et al., 1995 ¹⁴ Unpublished report, Lasermedics, Stafford, TX General Motors Study, Detroit, MI	119 subjects with CTS Half, real laser plus PT Half, sham laser plus PT Subjects treated for 5 weeks. Double-blind study	830 nm, CW 3 lasers in a cluster, 30 mW each laser (total diameter, 3 cm) 33 sec Tx cycle. Tx median nerve area, wrist/palm. Therapist and patient wore goggles	Tx same as real condition, however, no laser emission. Therapist and patient wore goggles	72% of subjects returned to work Sign. improvement in grip and pinch strength, $p < 0.05$ Sign. improvement in median μ motor latency, $p < 0.05$	41% of subjects returned to work No significant improvement, grip and pinch strength No significant improvement in motor latency	
Naeser et al., 2002 ³⁵ VA Boston Health-care System Boston University School of Medicine, Boston, MA	11 CTS cases, 9 M, 2F 3-30 mo. of pain; average pain, 16 mo. Randomized, double-blind, crossover study Each subject, 9-12 real laser and <i>subthreshold</i> , microamps TENS Tx's and 9-12 sham laser and microamps TENS Tx's (Every other day, 3 times per week) 3-4 weeks, each condition	632.8 nm, HeNe CW 15 mW on shallow acupuncture points, on wrist/hand area. 225 J/cm ² at PC 7 at wrist crease. Other points, 32.3 J/cm ² (see text) 904 nm, pulsed 9.4 W on deeper acupuncture points, forearm, shoulder, cervical neck, <1-2 J/cm ² per point. Microamps TENS, 20 min, across wrist	Tx same as real condition, however, no laser emission and no microamps TENS current emitted. Patient's hand was treated behind a hanging black curtain with red-beam laser and microamps TENS. (904 nm laser beam was not visible.)	87.5% of cases (7/8) pain decreased by $\geq 50\%$ during real; $p = 0.0035$ (Melzack). Significant decrease in median μ sensory peak latency, $p = 0.009$ Phalen sign improved, $p = 0.01$. Tinel sign improved, $p = 0.025$ Recommended criterion for good response: motor latency ≤ 7.0 msec	27.3% of cases (3/11), pain decreased by $\geq 50\%$ during sham. Other 8/11 cases, pain not reduced, $p = 0.41$, n.s. (Melzack) No significant decrease in median μ sensory peak latency, $p = 0.98$, n.s. Phalen sign not improved, $p = 0.96$, n.s. Tinel sign not improved, $p = 0.29$, n.s.	
1b. Three open-protocol studies that observed real laser to have a beneficial effect to treat CTS						
Wong et al. 1995 ⁴² Office Workers, San Francisco, CA	35 F subjects, CTS or RSI, 1 mo. to 10 yr. of pain, average pain 21 mo., all subjects real laser plus corrective posture and work ergonomics program, subjects treated during an 8-mo. period, 10 Tx's	830 nm, CW 100 mW laser 12-30 Joules per point, Tx only points at tip of spinous processes between cervical 5 to thoracic 1	No control group	91.4% of subjects "successfully treated"	No control group	

Weintraub, 1997 ⁴³ Private Practice Neurology Office, Briarcliff Manor, NY	30 hands with CTS, 14 F, 16 M, 2 mo. to 10 yr. of pain, average pain 24.4 mo., all subjects real laser 7-15 treatments	830 nm, CW 3 lasers in a cluster, 30 mW each laser (total diameter, 3 cm) 9 Joules per point, treated five points along median nerve area, wrist/palm	No control group	77% cases, CTS reversed. Normalization of distal latencies for com- pound muscle action potential in 36.6%. "Tendency to improve," 23%.	No control group
Branco and Naeser, 1999 ⁴¹ Private Practice Acupuncture Office, Westport, MA	36 hands, 31 CTS cases, 22 F, 9 M, 2 mo. to 18 yr. of pain, average pain 24 mo., 14 hands had failed 1-2 surgeries for release of transverse carpal ligament, all sub- jects real laser and microamps TENS plus acupuncture, supplements. 12-15 Tx's (3 times per week), 4-5 weeks	670 nm, CW 5 mW on shallow acupuncture points, on wrist/hand area. 32 J/cm ² at wrist crease. Other points, 4 J/cm ² (see text). 904 nm, pulsed 10 W on deeper acupuncture points, elbow, shoulder, cervical neck, <1-2 J/cm ² per point. Microamps TENS, 20 min, across wrist	No control group	91.6% of cases, pain decreased by at least 50%, Melzack Pain Questionnaire, $p < 0.0001$. 14/14 hands that had failed surgical treat- ment, pain relieved post-laser. Cases <60 yr. of age, 23/24 hands suc- cessful pain relief, 100% remained employed.	No control group
1c. Two studies that did not observe real laser to have a better effect than a control condition, to treat CTS					
Bakhtiary and Rashidy-Pour, 2004 ⁴⁶ Rehabilitation Faculty, Sennan Medical Sciences University, Sennan, Iran	50 subjects with CTS, 15 daily Tx's, 5 Tx's per week, real laser vs. ultrasound	830 nm, CW 1.8 Joules per point over the course of five points along the median nerve at the wrist.	Ultrasound Tx 1 MHz, 1.0 W/cm ² Pulse 1:4 15 min per session	Improvement was better in the ultrasound group, than in the laser group in: motor latency, motor action potential amplitude, finger pinch strength, hand grip strength, and pain relief.	
Irvine et al., 2004 ⁴⁷ Physical Medicine and Rehabilitation, University of Alberta, Edmonton, Alberta, Canada	15 subjects with CTS, double-blind randomized study 7 cases real laser, 8 cases sham laser, each treated 3 times per week, 5 weeks	860 nm, CW 6 J/cm ² per point over the carpal tunnel.	Tx same as real condition, however, no laser emission.	Significant "symptomatic improvement" post-real laser, $p = 0.043$ No significant difference in any outcome measure between the two groups in: Levine CTS questionnaire, electrophysiological data and Purdue Pegboard Test.	Significant "symptomatic improvement" post- sham laser, $p = 0.034$

CTS, carpal tunnel syndrome; J/cm², Joules per cm² energy density per point; RSI, repetitive strain injury; PT, physical therapy; CW, continuous wave laser beam; n.s., not significant.

to treat CTS; and (3) two studies that did not observe real laser to have a better effect than a control condition, to treat CTS.

For over two decades, photoradiation has been used to treat pain associated with musculo-skeletal injuries, arthritic conditions, and postherpetic neuralgia, to name a few.¹⁸⁻²³ Some mechanisms underlying therapeutic effects with photoradiation have been reviewed elsewhere²⁴⁻²⁶ and include the following: (1) increased adenosine triphosphate (ATP) production by the mitochondria²⁷ and increased oxygen consumption on the cellular level²⁸; (2) increased serotonin²⁹ and increased endorphins (naloxone has been observed to block the analgesic effect of photoradiation with GaAlAs laser)³⁰; and (3) anti-inflammatory effects.^{31,32} The primary effects are photobiologic, rather than photothermal.³³

TWO CONTROLLED STUDIES THAT OBSERVED REAL LASER TO HAVE A BETTER EFFECT THAN SHAM LASER TO TREAT CTS

In 1995, General Motors reported a double-blind study with photoradiation to treat CTS.³⁴ This included 119 subjects; half were randomly assigned to physical therapy (PT) plus real laser treatment, and half, PT plus sham laser. The MicroLight 830 Laser System (Lasermedics, Stafford, TX) was used. The manufacturer reports this laser to be 830 nm (near infrared) with a penetration of 3–5 cm into tissue “sufficient to penetrate the median nerve within the carpal tunnel.”³⁴ The device has three lasers comprising a single system (covering a 3-cm-diameter area) with a mean power output of 90 mW (30 mW per laser), timed to deliver a 33-sec treatment cycle. The laser was positioned over the involved wrist and palm, along the median nerve pathway. Eye safety glasses absorbent for 830 nm were worn by both the patient and the PT; neither knew which laser was real or sham. Patients were treated for 5 weeks.

The major finding was the significantly higher incidence of return to work post-treatment in the real laser group (72%) versus the sham laser group (41%) ($p < 0.05$).³⁴ There was significantly greater improvement post-real laser in grip and pinch strength ($p < 0.05$). There was also significant improvement in nerve conduction for the motor latency across the wrist post-real laser (*pre*: mean, 4.77 msec; SD, 0.70; and *post*: mean, 4.33 msec; SD, 0.81; $p < 0.05$, $n = 27$ wrists), but not post-sham laser (*pre*: mean, 4.54 msec; SD, 0.67; and *post*: mean, 4.39 msec; SD, 0.57; n.s., $n = 37$ wrists). In February, 2002, the U.S. Food and Drug Administration cleared the MicroLight 830 as the first Class IIb laser to be used in the non-surgical treatment and management of CTS.

In 2002, Naeser et al. published results from a controlled study at the VA Boston Healthcare System, where real laser and microcurrent, versus sham were investigated to treat CTS.³⁵ Microcurrent was included as an adjunctive treatment modality because similar to red-beam photoradiation,²⁷ it increases ATP.³⁶

Rationale for microamps TENS to treat pain

Most standard TENS (transcutaneous electrical nerve stimulation) devices use milliamps, which is applied *suprathreshold*; the patient feels a tingling sensation under the TENS pad. Mil-

liamps TENS is believed to reduce pain, in part, through the Gate Control Theory.³⁷ Microamps TENS (microcurrent) is applied *subthreshold*, and the patient feels nothing.

Microcurrent has an effect on ATP concentration and protein synthesis on the cellular level.³⁶ In the Cheng et al. study, ATP concentrations were increased by 300–500% in cells stimulated with constant currents of 25–1000 μ A; the greatest stimulatory effects were obtained around 500 μ A. Currents greater than 1.5 milliamps can *decrease* the ATP concentrations, and decrease the protein synthesis and transmembrane movement of metabolites.³⁶ Standard TENS devices are applied at suprathreshold level for the patient, and operate in the range of 20–80 milliamps and higher—levels that may deplete the cell's ATP and metabolic processing capabilities. Microcurrent has been used in a double-blind study to successfully treat chronic low back pain with 40 patients, where each patient received a total of 16 treatments.³⁸

In the Naeser et al. 2002 controlled study, 11 CTS cases (11 hands; nine male, two female) were treated (age 40–68 years, mean of 53.5 years). All had previously failed to obtain satisfactory pain relief with conservative treatments, including NSAIDs and wrist splints for a period of 3–30 months (mean of 16 months).

Patients were diagnosed with CTS based on a combination of NCSs, needle electromyography (EMG), and clinical findings. Those with mild CTS ($n = 6$) had only prolonged median nerve sensory peak latency (≥ 3.6 msec); those with moderate CTS ($n = 5$) had prolonged sensory latency *plus* prolonged motor latency (≥ 4.3 msec). Each patient also had at least two other signs and symptoms of CTS as listed above. No patient in the study had abnormality on needle EMG of the abductor pollicis brevis muscle.

Three devices were used:

1. A red-beam laser (continuous wave, 15 mW, 632.8 nm, HeNe gas tube laser with a 2-mm-diameter aperture; Dynatronics Model 1620, Salt Lake City, UT). The beam spot size was 0.031 cm²; the laser required 2 sec to produce 1 J/cm² energy density. The red-beam laser was applied to *shallow* acupuncture points located on the wrist, hand and fingers.
2. An infrared laser (pulsed, 180 nanoseconds “on” time, 9.4 W, 904 nm, GaAs diode laser with a 5-mm-diameter aperture; Respond Systems Model 2400, Branford, CT). A single diode laser probe, and a four-diode laser array were used. The latter consisted of four lasers that were embedded into a 6 × 6 cm block. Each diode laser in the array had the identical laser properties to that of the single diode laser probe. The infrared laser was applied to *deeper* acupuncture points located on the forearm, shoulder, and cervical paraspinal areas. Infrared lasers, with longer wavelengths, are believed to have deeper penetration than the red-beam lasers, with a more shallow penetration.
3. A microamps TENS device (580 μ A to 3.5 mA, model 100; MicroStim, Inc., Palm City, FL). This was applied to the affected wrist.

This was a randomized, double-blind, placebo-controlled, crossover trial. Staff administering the outcome measures were different from those administering the treatments. Staff administering the outcome measures (and patients) were blinded as

to which series of treatments (real or sham) each patient was about to receive, or had received. Staff administering the treatments were not blinded. Patients were tested on the outcome measures within a month prior to entry into the research (Entry Baseline), and within a week after the end of each treatment series (Post-Test #1 and Post-Test #2). The Post-Test #1 scores also served as Pre-treatment scores for the second treatment series.

Each patient received two, 3–4-week series of treatments, real and sham (order randomized). Patients were treated every other day, three times per week (9–12 treatments). Each session required 35–45 min. At the end of the first treatment series, patients were re-evaluated and then crossed over to the other treatment series, followed by post-testing. Seven cases received sham treatments *first*; four cases, real treatments *first*.

During sham laser, there was no emission from either the red or infrared lasers; the laser probe was held on the same acupuncture points for the same time. The microamps TENS device was turned off during sham treatment.

To guarantee that the patient remained blinded to which treatment condition he/she was receiving, all treatments were carried out on the affected upper extremity (UE), with the patient's arm placed underneath and through the bottom of a hanging black curtain to prevent the patient from seeing whether the red-beam laser was on or off (Fig. 1). The infrared laser is beyond the visible spectrum.

Treatments were administered by licensed acupuncturists with research acupuncture clinical privileges at the VA Boston Healthcare System. There were three steps:

Step 1. Red-beam laser on the wrist crease: The red-beam laser was placed directly on the skin (perpendicular) at the center of the distal wrist crease of the affected hand, acupuncture point pericardium (PC) 7, the point closest to the median nerve at the wrist crease (225 J/cm², 7.7 min).

Step 2. Microamps TENS on the wrist: The circular electrode (4 cm diameter) for the microamps TENS device was centered over acupuncture point PC 7 on the wrist crease, and the grounding pad was centered over acupunc-

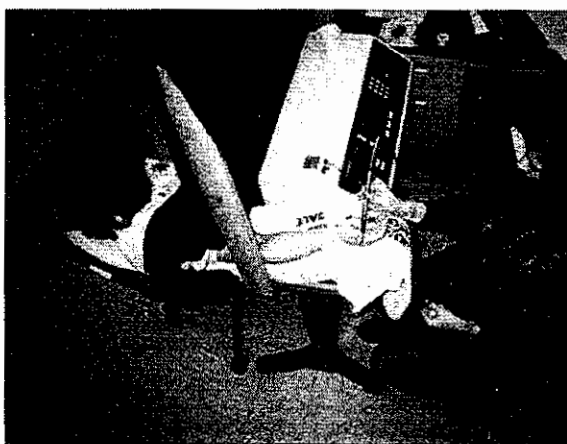


FIG. 1. In the controlled study, real versus sham photoradiation and microamps TENS, the CTS patient's hand was treated behind a hanging black curtain, so that the red-beam laser could not be seen by the patient.

ture point Triple Warmer (TW) 4, on the dorsum of the wrist (Fig. 1). The power on the microamps TENS was gradually increased until a slight tingling sensation was felt at either electrode site, then it was *immediately* turned down until there was no sensation at all (*subthreshold* level). The ideal setting is 200–500 μ A. After the *subthreshold* level had been established and set, a pulsed frequency of 292 Hz was used for 2 min, followed by a pulsed frequency of 0.3 Hz for 18 min (manufacturer suggested). The total time was 20 min. The MicroStim 100 TENS device uses a 15,000-Hz carrier wave with a bi-phasic current. During sham treatment, the same procedure was followed; however, the TENS device was turned off immediately after the subthreshold intensity had been established. The patient felt nothing from the microamps TENS treatment during the real or sham condition.

Step 3. Red-beam laser and infrared laser treatment of acupuncture points: During the 20-min microcurrent TENS treatment, the red-beam laser was applied to additional acupuncture points on the affected fingers and hand (32.3 J/cm², 66.6 sec per point). The points on the fingers included Lung (LU) 11, Large Intestine (LI) 1, PC 9, TW 1, Heart (HT) 9, and Small Intestine (SI) 1. These were chosen because they represent the origin and termination for six acupuncture meridians which pass through the wrist. Other points chosen for treatment on the wrist and hand, LU 9, HT 7, HT 8, PC 8 and Ba-Xie points in the web-spaces between the fingers, were chosen because they are local acupuncture points for treatment of hand pain. Also during Step 3, the infrared laser was applied to a minimum of five, deeper acupuncture points on the UE, and the cervical neck. Each acupuncture point was treated for a minimum of 1 min, at each of three pulse settings—e.g., 3,500, 584, and 73 pulses per second (pps), with energy densities ranging from 1.81 J/cm² at the highest frequency to 0.04 J/cm² at the lowest frequency. The acupuncture points treated on the UE varied in each case, depending on the locus and direction of radiating pain. Potential points included TW 5, 9; PC 6; LI 10, 11 and 15. The acupuncture points on the cervical paraspinal area included Hwa To points lateral to cervical 5 to thoracic 1. Other acupuncture points included GB 20; SI 10, 11 or other locally painful points.

Results

A patient was considered to have good response if the Melzack pain score³⁹ showed at least a 50% reduction, post-real or post-sham treatment.

Melzack pain scores

A patient who reported >50% pain reduction following a series of *sham* treatments was considered to be a placebo responder. Three cases were placebo responders, including two of the seven cases who received sham treatments *first* and one case who received sham treatments *second*. This overall placebo response rate of 3/11 (27.3%) is consistent with placebo response where sham photoradiation has been included to treat pain.²⁰ These three placebo responders were removed from all further statistical analyses of the Melzack pain scores for *real*, as well

as sham treatment. A comparison of Melzack pain scores for the remaining eight subjects receiving sham laser established there was no change from pre- to post-sham treatment ($p = 0.41$).

There was a significant reduction in pain post-real treatment, $n = 8$ ($p = 0.0035$), representing a mean reduction of -18.13 points on the Melzack pain scores ($SD = 10.45$), or -88.78% ($SD = 28.27$). This represented a sixfold reduction in pain; pre-real, 21.87 ($SD = 9.06$) and post-real, only 3.75 ($SD = 6.52$). Overall, 7/8 cases reported $>50\%$ pain reduction post-real treatment, a success rate of 87.5% . (The remaining case decreased pain by 25% .) Six of eight cases (75%) reported a Melzack pain score of ≤ 2 ; four of these cases, 0 (Fig. 2).

Sensory latencies

The mean change post-sham treatment was 0.003 msec ($SD = 0.48$), $p = 0.98$, n.s. The mean decrease in sensory latency post-real treatment was -0.215 msec ($SD = 0.17$), $p = 0.009$. Seven of the eight cases (87.5%) showed a decrease, and one case showed no change, post-real treatment.

Motor latencies

There was no significant change in the motor latencies post-sham treatment ($p = 0.19$), or post-real treatment ($p = 0.27$).

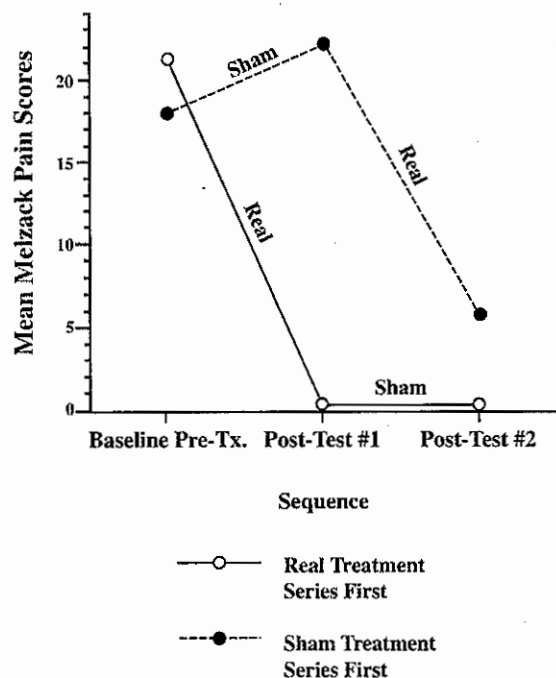


FIG. 2. Mean Melzack pain scores for 8 CTS cases separated into two treatment groups (the 3 placebo responders have been omitted): (1) cases receiving the real treatment series first, and the sham, second ($n = 3$), and (2) cases receiving the sham treatment series first, and the real, second ($n = 5$). For the pooled groups ($n = 8$), there was a significant decrease in pain post-real ($p = 0.0035$), but not post-sham ($p = 0.41$). Reprinted with permission from Naeser et al.³⁵ and from American Congress of Rehabilitation Medicine and the Academy of Physical Medicine and Rehabilitation.

Phalen sign

There was no significant decrease in the number of cases with positive Phalen sign post-sham ($p = 0.96$): pre-sham, 6/8 cases (75%) had positive Phalen, and post-sham, 5/8 cases (62.5%). There was, however, a significant decrease in the number with positive Phalen post-real ($p = 0.014$): pre-real, 9/11 cases (81.8%) had positive Phalen, and post-real, only 2/11 cases (18.2%), positive Phalen.

Tinel sign

There was no significant change from pre- to post-sham ($p = 0.29$). However, the positive Tinel sign was reversed post-real laser, whereas 6/6 cases had positive Tinel sign pre-real, 0/6 patients, post-real ($p = 0.025$).

All patients were able to resume prior work activities with less or no pain (e.g., computer typist, handyman worker, house painter, plumber). All remained stable in their pain reduction at 1–3 years follow-up, except for a woman, age 59, with insulin-dependent diabetes since age 21 (a placebo responder), who had sustained a brain-stem and left frontal lobe stroke affecting the CTS hand 2 years prior to photoradiation. Her CTS pain returned within 1 year. Follow-up red-beam photoradiation and microamps TENS self-administered treatments at home,⁴⁰ and later steroid injection into the carpal canal failed to provide pain relief beyond a 3-month period in this case with both central and peripheral nervous system damage. Similar complications were observed in one CTS case who later had a stroke, in the open-protocol study of Branco and Naeser.⁴¹

Summary

In the real laser treatment groups, Anderson et al.³⁴ had a success rate of 72% , and Naeser et al.³⁵ had a success rate of 87.5% , compared to 41% and 27.3% in the sham laser groups. Each study observed significant improvements at the $p < 0.05$ level and beyond, post-real laser, but not post-sham. These included increased number of subjects returning to work, increased grip and pinch strength, and decreased median nerve motor latency³⁴; as well as decreased pain, decreased sensory peak latency, and decreased Phalen and Tinel signs.³⁵ These two successful studies used laser dosages at the median nerve area at the wrist of 9 Joules³⁴ and 225 J/cm^2 ,³⁵ as well as treatment of additional points near the affected area. Naeser et al. applied laser to acupuncture points and also applied microcurrent through the wrist, plus additional acupuncture points were treated on the UE and cervical neck area with infrared laser.

THREE OPEN-PROTOCOL STUDIES THAT OBSERVED REAL LASER TO HAVE A BENEFICIAL EFFECT TO TREAT CTS

In 1995, an open-protocol photoradiation study was published by Wong et al.⁴² with office workers who had CTS or repetitive strain injury (RSI). A total of 35 cases (all female; ages 26–61, average age of 42) were treated. Pain duration ranged from 1 month to 10 years (average of 21 months). A near-infrared, 830-nm, 100-mW laser (DioLase-TM 100) was

used. A total of 12–30 Joules was applied per point *only* at the posterior neck region, at the tip of the spinous processes between cervical 5 to thoracic 1, *not* the affected wrist/hand area. The subjects were also given a corrective posture program and provided improved work ergonomics. Results showed that, over an 8-month period (10 treatments), 91.4% of cases were successfully treated.

In 1997, Weintraub⁴³ reported positive results with CTS patients who were treated with the MicroLight 830 laser (for laser information, see Anderson et al.³⁴). A total of 30 hands (14 female, 16 male) were treated. The pain duration ranged from 2 months to 10 years (average of 24.4 months). The laser was applied to the involved wrist and palm, along the median nerve pathway. A total of 9 Joules was used per point, over five points. Patients received 7–15 treatments. Results showed a normalization of distal latencies for compound muscle action potential in 11 hands, and tendency to improve in 23%, reversing CTS in 77%. Weintraub concluded that photoradiation “is a safe, cost-effective alternative therapy . . . and appears to be an attractive substitute for surgery.”

In 1999, an open protocol study was published by Branco and Naeser where 31 CTS cases (22 female, 9 male) were treated with a combination of photoradiation and microamps TENS, as the primary treatment modalities.⁴¹ Treatment was based on the protocol from Naeser and Wej⁴⁰ and Naeser et al.⁴⁴ The study took place in a private practice acupuncture office.

Thirty-six hands were treated. The age at entry was 24–84 years (median of 50 years). The age distribution for the 36 hands treated was as follows: <40 years, $n = 8$ hands; age 40–60 years, $n = 16$; and >60 years, $n = 12$. All patients had previously received standard medical treatment without successful pain relief. This included NSAIDs and wrist splints. Also, 17/36 hands (47.2%) had been treated with one to three cortisone injections; and 14/36 hands (38.8%) had received one to two surgeries for release of the transverse carpal ligament, but pain remained. The duration of pain ranged from 2 months to 18 years (median of 24 months). The CTS diagnosis was made by the patients’ physicians. Prior to the first treatment and immediately following the last treatment, each patient was administered the Melzack Pain Questionnaire.³⁹ Patients were treated every other day, 3 days a week, for 4–5 weeks (12–15 treatments). Each treatment lasted 45 min.

The three types of equipment (red-beam laser, infrared laser, and microamps TENS) used in this Branco and Naeser study were identical to those in the Naeser et al. controlled study,³⁵ with the exception of the type of red-beam laser. A 5-mW, 670-nm, red-beam, laser pointer (LP 5F1, ITO brand) was used instead of the 15-mW HeNe gas tube laser. The 5-mW laser pointer had an aperture of 5 mm diameter; the beam spot size was 0.196 cm²; 39.2 sec was required to produce 1 J/cm² energy density. The same three steps used in Naeser et al.³⁵ were used in this study; however, the energy densities were lower for J/cm² used on some acupuncture points. The three steps were as follows:

Step 1. Red-beam laser on the wrist crease: The laser was placed on the median nerve area at the center of the distal wrist crease (acupuncture point, PC 7) for approximately 21 min (32.1 J/cm²). [In the research study, 225 J/cm² was used.³⁵]

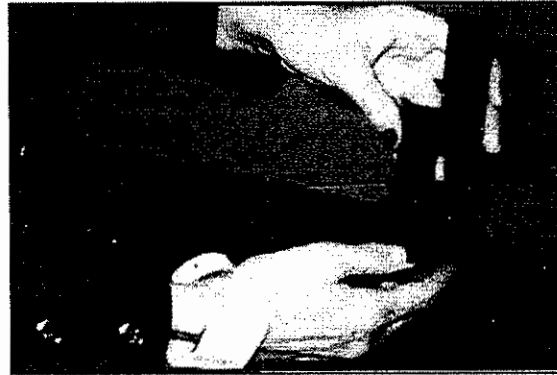


FIG. 3. Microamps TENS device in place at the wrist, so that the microcurrent passes through the wrist (Step 2). The laser pen is shown on acupuncture point LU 11 (part of Step 3). Reprinted with permission from Branco and Naeser.⁴¹

Step 2. Microamps TENS on the wrist: The MicroStim 100 TENS device (MicroStim Inc., Palm City, FL) was used with the same protocol³⁵ (Fig. 3).

Step 3. Red-beam laser and infrared laser treatment of acupuncture points: During the 20-min microcurrent TENS treatment, the red-beam laser was applied to other acupuncture points on the affected hand, for 3 min per point (4 J/cm² per point). The acupuncturist used two to four laser pointers to treat two to four points at once, in order to save time. Also, the pulsed, 10-W, 904-nm, infrared laser (Respond Laser model 2400, Respond Systems, Branford, CT) was used on deeper acupuncture points on the forearm, shoulder, and cervical neck area in the same manner.³⁵

Additional secondary, alternative treatment modalities

Oriental medicine therapies were used on a case-by-case basis, including Chinese herbal medicine formulas, supplements, moxibustion, and/or needle acupuncture.⁴⁵

Melzack pain scores

Post-treatment, the pain was significantly reduced ($p < 0.0001$), and 33/36 hands (91.6%) reported no pain, or pain reduced by at least 50% (Fig. 4). There was a mean pain reduction of -28.5 points (SD, 13.5); pre-treatment, 32.1 (SD, 11.6); post-treatment, 3.6 (SD, 8.1). The 14 hands that had failed surgical release were successfully treated, including two patients who had failed two surgical release procedures on the same hand.

Among the patients <60 years old, 18/19 cases (23/24 hands, 95.8%) were successfully treated and the patients remained employed (secretary, repair service, maintenance worker, auto body mechanic, teacher, computer operator, nurse’s aid, artist/painter, nail technician, photographer, factory worker, ice cream server). Follow-up after 1–2 years with these cases showed that, in only 8.3% of successfully treated hands, the pain returned (2/23 hands), but this was successfully re-treated within a few weeks of the photoradiation and microamps TENS treatments.

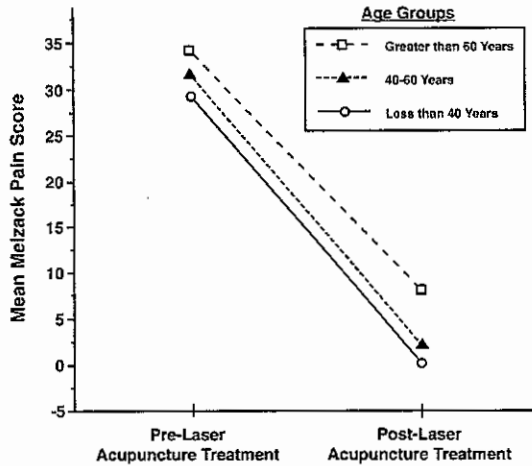


FIG. 4. Mean Melzack pain scores for three separate age groups, pre- and post-laser acupuncture treatment. A repeated measures ANOVA showed a main effect of laser acupuncture treatment ($p < 0.0001$), but no effect of age group and no interaction between age group and laser acupuncture treatment. Reprinted with permission from Branco and Naeser.⁴¹

In patients >60 years old, 10/12 cases (10/12 hands, 83.3%) were successfully treated; all were retired. Five patients required follow-up treatments within 1 year. In 4/5 of these cases (80%), pain relief was again achieved. In the one patient (age 81) who did not achieve pain relief with re-treatment, there was a stroke 2 months post-laser treatment.

Nerve conduction studies

Data from NCSs and EMG were available for only six cases, all >60 years old. The two patients who had poor response either had abnormality on EMG or a motor latency which was >7 msec (e.g., 7.08 msec) at entry. One patient with good response, with no abnormality on EMG, but a motor latency of 8.6 msec, had a re-occurrence of pain 2 months post-laser treatment (following an acute stroke), and follow-up treatments were unsuccessful. NCS data for three patients with good response showed each had a motor latency of <7 msec (3.75, 4.3, and 5.3 msec) pretreatment.

Patients with abnormality on EMG and/or a motor latency of >7 msec are not good candidates for photoradiation. In the Naeser et al. controlled study,³⁵ the motor latency at entry for the moderate CTS cases who had good response post-real laser ranged from 4.6 to 5.6 msec. Thus, patients with no abnormality on EMG and motor latency of ≤ 7 msec (sensory latency may be absent) are likely ideal candidates for this new, conservative treatment for CTS.

Summary

Results from these three open-protocol studies are similar to those from the controlled studies where significant improvement was observed with real, but not sham laser.^{34,35} The success rate for treatment of CTS in these open-protocol studies ranged from 77%⁴³ to 91%.^{41,42} The success rates following real laser in the controlled studies ranged

from 72%³⁴ to 87.5% study.³⁵ The mean success rate across the five studies was 84% (SD, 8.9); total hands treated (real laser) was 171.

A shared laser treatment parameter across the two controlled laser studies, and these three open-protocol studies, was application of a higher laser dosage to primary treatment areas. Wong et al. used 12–30 Joules at the tip of the spinous processes between C5 and T1⁴²; Weintraub used 9 Joules per point, at five points along the median nerve⁴³; and Branco and Naeser used 32 Joules/cm² on the acupuncture point PC 7, the nearest point to the median nerve at the wrist crease.⁴¹ The controlled studies used 9 Joules and 225 J/cm² applied on the median nerve area at the wrist.^{34,35} The open-protocol studies of Wong et al. and Branco and Naeser also documented a continued employment rate of at least 91%.^{41,42} In the controlled studies, continued employment of at least 72% was observed with real laser.^{34,35}

TWO STUDIES THAT DID NOT OBSERVE REAL LASER TO HAVE A BETTER EFFECT THAN A CONTROL CONDITION, TO TREAT CTS

In 2004, Bakhtiary and Rashidy-Pour reported results where ultrasound versus laser therapies were examined to treat CTS in 50 patients.⁴⁶ Ultrasound consisted of 1 MHz, 1.0 W/cm², pulse 1:4, 15 min per session. The photoradiation treatment with an 830-nm infrared laser consisted of 1.8 Joules per point over the course of the median nerve at the wrist (total, 9 Joules). Patients were treated for 15 daily treatments (five treatments per week). Improvement was reported to be better in the ultrasound group than in the photoradiation group, for motor latency, motor action potential amplitude, finger pinch, hand grip strength, and pain relief. Effects were sustained in the follow-up period at 4 weeks post-treatment. Further research was recommended to investigate the combination of ultrasound and photoradiation to treat CTS.

Also in 2004, Irvine et al. conducted a double-blind, randomized controlled trial with photoradiation to treat 15 CTS patients, ages 34–67.⁴⁷ Eight patients received sham laser, and seven patients, real laser. Each group was treated three times per week for 5 weeks. Those receiving real laser were treated with an 860-nm infrared laser at a dosage of 6 J/cm² over the carpal tunnel. The primary outcome measure was the Levine Carpal Tunnel Syndrome Questionnaire; secondary measures were electrophysiological data and the Purdue pegboard test. There was significant symptomatic improvement in both the sham laser group ($p = 0.034$) and the real laser group ($p = 0.043$). There was no significant difference in any of the outcome measures between the two groups. The authors concluded that real laser was no more effective than sham laser in the reduction of symptoms of CTS.

Summary

Each of these two studies had applied a lower laser dosage to the median nerve area (1.8 Joules⁴⁶ and 6 J/cm²⁴¹), than the five studies that reported beneficial effect from photoradiation (9 Joules^{34,43}; 32 J/cm²⁴¹; 225 J/cm²³⁵ to the median nerve area; or 12–30 Joules at C5 to T1⁴²).

CONCLUSION

With an average success rate of 84% (SD, 8.9) across the five positive photoradiation studies (171 hands treated, real laser), photoradiation is a promising new, conservative treatment for CTS in the earlier stages, before irreversible damage has occurred in the median nerve. Two studies suggest that ideal candidates should have a motor latency <7 msec and no abnormality on needle EMG.^{35,41} Across the five positive studies, prior to successful treatment with photoradiation, the average pain duration had been 2 years. Possible mechanisms underlying significant improvement post-laser include increased ATP,²⁷ improved cellular respiration,²⁸ increased serotonin²⁹ and endorphins,³⁰ and decreased inflammation.^{31,32} An increase in ATP has also been suggested following microcurrent.³⁶ The estimated cost to treat one CTS case with conservative treatment (without surgery) is \$5,246.¹⁷ The cost with the photoradiation is around \$1,000 (\$65 per office visit × 15 visits = \$975). Thus, in addition to a success rate of about 84% in treating CTS when higher laser dosages are used, there is potential for cost-savings of at least \$4,000 per case.

DEDICATION

This paper is dedicated to the late John Ramey, of Dynatronics Corp., Salt Lake City, UT, who provided invaluable assistance in the 1990s with the VA Boston Healthcare System photoradiation research project to treat CTS.

REFERENCES

1. Stevens, J.C. (1997). *AAEM Minimonograph #26: The Electrodiagnosis of Carpal Tunnel Syndrome, revised 1997*. Rochester, MN: American Association of Electrodiagnostic Medicine.
2. Katz, J.N., Larson, M.G., Sabra, A., et al. (1990). The carpal tunnel syndrome: diagnostic utility of the history and physical examination findings. *Ann. Intern. Med.* 112, 321-327.
3. Dawson, D.M. (1995). Entrapment neuropathies of the upper extremities. *N. Engl. J. Med.* 329, 2013-2018.
4. Hennessey, W.J., and Kuhlman, K.A. (1997). The anatomy, symptoms and signs of carpal tunnel syndrome, in: *Physical Medicine and Rehabilitation Clinics of North America. Carpal Tunnel Syndrome*. G.H. Kraft and E.W. Johnson (eds.). Philadelphia: Saunders, pp. 439-457.
5. Jablecki, C.K., Andary, M.T., So, Y.T., et al. (1999). Literature review of the usefulness of nerve conduction studies and electromyography for the evaluation of patients with carpal tunnel syndrome. *Muscle Nerve Suppl.* 8, S145-S167.
6. Vennix, M.J., Hirsh, D.D., Faye, Y.C.T., et al. (1998). Predicting acute denervation in carpal tunnel syndrome. *Arch. Phys. Med. Rehabil.* 8, 306-312.
7. U.S. Department of Labor, Bureau of Labor Statistics. (1983). *Occupational Injuries and Illnesses in the United States by Injury, 1981*. Washington, DC: U.S. Government Printing Office.
8. U.S. Department of Labor, Bureau of Labor Statistics. 1993. *Occupational Injuries and Illnesses in the United States by Injury, 1991*. Washington, DC: U.S. Government Printing Office.
9. U.S. Department of Labor, Bureau of Statistics. 1995. BLS reports rise in cumulative trauma. *Occup. Health Safety* 64(1), 18-20.
10. Feuerstein, M., Burrell, L.M., Miller, V.I., et al. (1999). Clinical management of carpal tunnel syndrome: a 12-year review of outcomes. *Am. J. Industr. Med.* 35, 232-245.
11. Slater, R.R., Jr., and Bynum, D.K. (1993). Diagnosis and treatment of carpal tunnel syndrome. *Orthop. Rev. Oct.* 1095-1105.
12. Gelberman, R.H., Aronson, D., and Weisman, M.H. (1980). Carpal tunnel syndrome: results of a prospective trial of steroid injection and splinting. *J. Bone Joint Surg. (Am.)* 62A, 1181.
13. Duncan, K.H., Lewis, R.C., Foreman, K.A., et al. (1987). Treatment of carpal tunnel syndrome by members of the American Society for Surgery of the Hand: results of a questionnaire. *J. Hand Surg. (Am.)* 12, 384-391.
14. Cseuz, K.A., Thomas, J.E., Lambert, E.H., et al. (1966). Long-term results of operation for carpal tunnel syndrome. *Mayo Clin. Proc.* 41, 232-241.
15. Armstrong, M.B., and Villalobos, R.E. (1997). Surgical treatment of carpal tunnel syndrome, in: *Physical Medicine and Rehabilitation Clinics of North America, Carpal Tunnel Syndrome*. G.H. Kraft and E.W. Johnson (eds.). Philadelphia: Saunders, pp. 529-539.
16. CTDs taking bigger bite of corporate bottom line. *CTD News* 1995;4:1.
17. Clairmont, A. (1997). Economic aspects of carpal tunnel syndrome, in: *Physical Medicine and Rehabilitation Clinics of North America, Carpal Tunnel Syndrome*. G.H. Kraft and E.W. Johnson (eds.). Philadelphia: Saunders, pp. 571-576.
18. Kleinkort, J.A., and Foley, R.A. (1984). Laser acupuncture: its use in physical therapy. *Am. J. Acupuncture* 12, 51-56.
19. Soriano, F., and Rios, R. (1998). Gallium arsenide laser treatment of chronic low back pain: a prospective, randomized and double blind study. *Laser Ther.* 10, 175-180.
20. Fukuchi, A., Suzuki, H., and Inoue, K. (1998). A double-blind trial of low reactive-level laser therapy in the treatment of chronic pain. *Laser Ther.* 10, 59-64.
21. Moore, K.C., Hira, N., Kumar, P.S., et al. (1988). A double blind crossover trial of low level laser therapy in the treatment of post herpetic neuralgia. *Lasers Med. Sci.* July, 301.
22. McKibben, L.S., and Downie, R. (1990). Treatment of postherpetic pain using a 904-nm low-energy infrared laser. *Laser Ther.* 2, 20.
23. Kemmotsu, O., Sato, K., Furumido, H., et al. (1991). Efficacy of low reactive-level laser therapy for pain attenuation of postherpetic neuralgia. *Laser Ther.* 3, 71-75.
24. Basford, J.R. (1989). Low-energy laser therapy: controversies and new research findings. *Lasers Surg. Med.* 9, 1-5.
25. Tam, G. (1999). Low power laser therapy and analgesic action. *J. Clin. Laser Med. Surg.* 17, 29-33.
26. Tuner, J., and Hode, L. (2002). *Laser Therapy: Clinical Practice and Scientific Background*. Grangesberg, Sweden: Prima Books.
27. Passarella, S. (1989). He-Ne laser irradiation of isolated mitochondria. *J. Photochem. Photobiol.* 3, 642-643.
28. Yu, W., Naim, J.O., McGowan, M., et al. (1997). Photomodulation of oxidative metabolism and electron chain enzymes in rat liver mitochondria. *Photochem. Photobiol.* 66, 866-871.
29. Walker, J. (1983). Relief from chronic pain by low power laser irradiation. *Neurosci. Lett.* 43, 339-344.
30. Yamamoto, H., Ozaki, A., Iguchi, N., et al. (1988). Antinociceptive effects of laser irradiation of Hoku point in rats. *Pain Clin.* 8, 43-48.
31. Ailioaie, C., and Lupusoru-Ailioaie, L.M. (1999). Beneficial effects of laser therapy in the early stages of rheumatoid arthritis onset. *Laser Ther.* 11, 79-87.
32. Mester, E., Mester, A.F., and Mester, A. (1985). The biomedical effects of laser application. *Lasers Surg. Med.* 5, 31-39.
33. Karu, T.I. (1987). Photobiological fundamentals of low-power laser therapy. *IEEE J. Quantum Electronics* QE-23, 1703-1717.

34. Anderson, T.E., Good, W.T., Kerr, H.H., et al. (1995). Low-level laser therapy in the treatment of carpal tunnel syndrome. [Unpublished report]. Stafford, TX: Lasermedics.
35. Naeser, M.A., Hahn, K.-A.K., Lieberman, B.E., et al. (2002). Carpal tunnel syndrome pain treated with low-level laser and microamps TENS, a controlled study. *Arch. Phys. Med. Rehabil.* 83, 978-988.
36. Cheng, N., Van Hoof, H., Bockx, E., et al. (1982). The effects of electric currents on ATP generation, protein synthesis, and membrane transport in rat skin. *Clin. Orthop.* 171, 264-272.
37. Melzack, R., and Wall, P.D. (1965). Pain mechanisms: a new theory. *Science* 150, 971-979.
38. Meyer, F.P., and Nebrensky, A. (1983). A double-blind comparative study of microstimulation and placebo effect in short-term treatment of the chronic back pain patient. *Calif. Health Rev.* 2, 1.
39. Melzack, R. (1975). The McGill pain questionnaire: major properties and scoring methods. *Pain* 1, 277-299.
40. Naeser, M.A., and Wei, X.B. (1994). *Laser Acupuncture—An Introductory Textbook for Treatment of Pain, Paralysis, Spasticity and Other Disorders*. Boston: Boston Chinese Medicine.
41. Branco, K., and Naeser, M.A. (1999). Carpal tunnel syndrome: clinical outcome after low-level laser acupuncture, microamps transcutaneous electrical nerve stimulation, and other alternative therapies—an open protocol study. *J. Alternat. Complem. Med.* 5, 5-26.
42. Wong, E., Lee, G., Zucherman, J., et al. (1995). Successful management of female office workers with "repetitive stress injury" or "carpal tunnel syndrome" by a new treatment modality—application of low level laser. *Int. J. Clin. Pharm. Ther.* 33, 208-211.
43. Weintraub, M.I. (1997). Noninvasive laser neurolysis in carpal tunnel syndrome. *Muscle Nerve* 20, 1029-1031.
44. Naeser, M.A., Hahn, K.K., and Lieberman, B. (1996). Real vs. sham laser acupuncture and microamps TENS to treat carpal tunnel syndrome and worksite wrist pain: pilot study. *Lasers Surg. Med. Suppl.* 8, 7.
45. Wolfe, H.L. (1995). One approach to acumoxa therapy for pain due to tendinitis of the hand, wrist, and forearm. *Am. J. Acupuncture* 23, 219-229.
46. Bakhtiary, A.H., and Rashidy-Pour, A. (2004). Ultrasound and laser therapy in the treatment of carpal tunnel syndrome. *Aust. J. Physiother.* 50, 147-151.
47. Irvine, J., Chong, S.L., Amirjani, N., et al. (2004). Double-blind randomized controlled trial of low-level laser therapy in carpal tunnel syndrome. *Muscle Nerve* 30, 182-187.

Address reprint requests to:

Dr. Margaret A. Naeser
VA Boston Healthcare System (12-A)
150 So. Huntington Ave.
Boston, MA 02130

E-mail: mnaeser@bu.edu